© Copyright by Uniwersytet Opolski
e-ISSN 2544-1620

Medical Science Pulse 2025 (19) 4

Published online: 19 December 2025 Reviews DOI: 10.5604/01.3001.0055.4601

ATYPICAL HEMOLYTIC-UREMIC SYNDROME (AHUS) – A RARE DISEASE, NEW HOPES IN TREATMENT: A SYSTEMATIC REVIEW

Marta Turek[1 A,C,E]
• ORCID: 0009-0005-7713-6875

Julia Szlążek[2 A,C,E]
• ORCID: 0009-0007-6977-8856

Michalina Zagalska[1 A,D,E]
• ORCID: 0009-0002-7312-0065

Kamil Kerknawi[3 F,E]
• ORCID: 0009-0009-9739-9954

Adam Jan Ząbek[4 D]
• ORCID: 0009-0003-6799-1814

Adam Grzebinoga[5 F]
• ORCID: 0009-0001-5983-7564

Jakub Paweł Kuźniar[6 C]
• ORCID: 0009-0002-6716-7502

Emilia Gabriela Chrzanowska[1 C]
• ORCID: 0009-0001-6228-1878

Barbara Roguska[2 B]
• ORCID: 0009-0006-6905-7517

Tomasz Tamborski[7 B]
• ORCID: 0009-0003-6275-1010

[1] Independent Public Clinical Hospital named Andrzej Mielęcki of the Silesian Medical University in Katowice, Poland
[2] Medical University of Silesia, Katowice, Poland
[3] Zagłębie Oncology Center in Dąbrowa Górnicza, Poland
[4] Katowice Oncology Center, Poland
[5] University Clinical Center of Prof. K. Gibiński of the Silesian Medical University in Katowice, Poland
[6] The Provincial Hospital in Bielsko-Biała, Poland
[7] County Hospital in Zawiercie, Poland

A – study design, **B** – data collection, **C** – statistical analysis, **D** – interpretation of data, **E** – manuscript preparation, **F** – literature review, **G** – sourcing of funding

ABSTRACT

Background: Atypical hemolytic uremic syndrome (aHUS) is a rare disease resulting from dysregulation of the complement system and manifests as thrombotic microangiopathy (TMA). It is a heritable, life-threatening disorder characterized by uncontrolled complement activation, leading to systemic TMA and damage to vital organs. aHUS is frequently considered a prototypical form of complement-mediated TMA (CM-TMA), caused by dysregulation and overactivation of the alternative complement pathway, culminating in excessive terminal complement activation. The classical clinical triad of aHUS includes thrombocytopenia, microangiopathic hemolytic anemia, and acute kidney injury.

Aim of the study: This review paper aims to provide a comprehensive overview of atypical hemolytic uremic syndrome (aHUS), including its pathomechanism, clinical presentation, and diagnostic criteria. Attention is also directed toward secondary aHUS, which may occur in association with various underlying conditions. Furthermore, this review covers currently available treatment modalities utilizing eculizumab and ravulizumab, providing a comparative analysis of these two agents and highlighting their significance as terminal complement pathway inhibitors.

Material and methods: This systematic review was conducted in accordance with the PRISMA guidelines. The literature search was performed using the PubMed database with the following MeSH terms: (atypical hemolytic-uremic syndrome) AND (treatment).

This is an Open Access article distributed under the terms of the Creative Commons License Attribution-NonCommercial-ShareAlike 4.0 International (CC BY-NC-SA 4.0). License available: https://creativecommons.org/licenses/by-nc-sa/4.0/

Results: The fundamental mechanism underlying aHUS is uncontrolled activation of the complement system, particularly its alternative pathway, leading to systemic TMA and life-threatening organ damage. The management of aHUS has been transformed by the introduction of terminal complement inhibitors, such as eculizumab and ravulizumab, which have demonstrated efficacy in improving hematological and renal parameters. Ravulizumab, a long-acting C5 inhibitor, allows for less frequent dosing compared to eculizumab.

Conclusions: This review emphasizes the importance of early recognition and the implementation of complement inhibitor therapy in aHUS and highlights the necessity for future comparative studies of eculizumab and ravulizumab to optimize treatment strategies.

Keywords: atypical hemolytic-uremic syndrome, treatment, eculizumab, ravulizumab, pathomechanism, diagnostic criteria, differential diagnosis

Background

Atypical hemolytic-uremic syndrome (aHUS) is a rare disorder resulting from dysregulation of the complement system and manifests as thrombotic microangiopathy (TMA) [1]. It is also described as a heritable, life-threatening condition characterized by uncontrolled activation of the complement system, systemic TMA, and damage to vital organs [9]. aHUS is frequently considered the prototypical form of complement-mediated thrombotic microangiopathy (CM-TMA), arising from dysregulation and overactivation of the alternative complement pathway, leading to excessive terminal complement activation [1]. The classical clinical triad of aHUS includes thrombocytopenia, microangiopathic hemolytic anemia, and acute kidney injury [1, 5–7]. TMA, the cardinal feature of aHUS, is characterized by a low platelet count ($<150\times10^9$/L) and microangiopathic hemolytic anemia [3]. It is also important to note the existence of secondary atypical hemolytic-uremic syndrome (secondary aHUS), which represents a heterogeneous group of thrombotic microangiopathies (TMAs) associated with various underlying conditions, such as pharmacological treatments, systemic diseases, pregnancy, malignancies, hematopoietic stem cell and organ transplantation, systemic infections, primary glomerulopathies, and monoclonal gammopathies [3].

AIM OF THE STUDY

The aim of this review is to provide a comprehensive overview of atypical hemolytic-uremic syndrome (aHUS). Specifically, the paper seeks to describe aHUS in terms of its pathomechanism, clinical presentation, and diagnostic criteria. It also discusses secondary forms of aHUS that may arise in association with various underlying conditions. Furthermore, the review evaluates available therapeutic modalities involving eculizumab and ravulizumab, comparing their mechanisms and significance as terminal complement pathway inhibitors.

Material and methods

Search strategy

This systematic review was conducted in accordance with the PRISMA guidelines [9]. The literature search was performed using the PubMed database with the following MeSH terms: (atypical hemolytic-uremic syndrome) AND (treatment). The aim was to collect both the most recent and previously available studies; therefore, the following filters were applied: "within the last 10 years" and "free full text availability." A total of 33 publications in English were identified and subsequently screened for eligibility based on predefined criteria. The search was performed in April 2025.

Eligibility criteria

The following inclusion criteria were applied to the retrieved studies:

- Population: adults over the age of 18 with symptoms of aHUS.
- Prognostic factor: studies describing the pathomechanism of aHUS and risk factors for the development of secondary aHUS.
- Outcome: articles containing research on newly available drugs and methods of treating aHUS.
- Language: publications written in English.
- Text availability: free full text available.

Exclusion criteria included studies on pediatric populations, reviews, expert opinions, letters to the editor, conference abstracts, and non–open-access publications.

Data collection

Each author independently reviewed the literature. Abstracts of all identified articles were screened

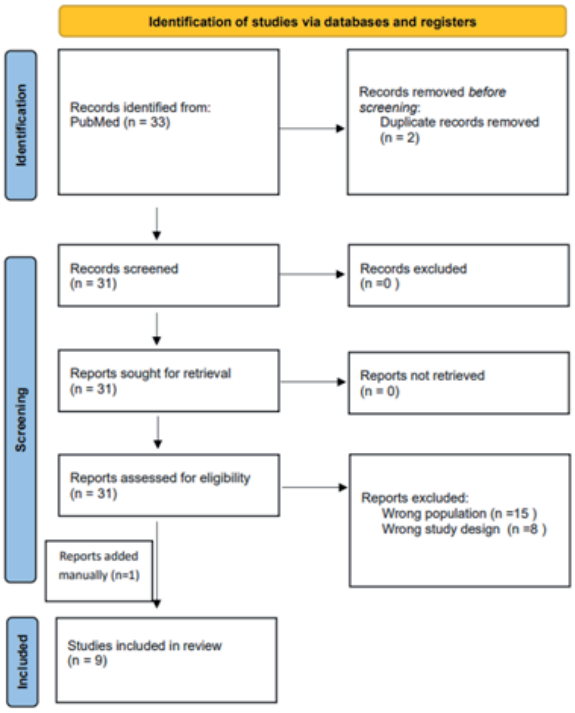

Figure 1. PRISMA flowchart for conducting the literature search [9]

to assess their relevance to the topic of atypical hemolytic-uremic syndrome, with a focus on modern therapeutic approaches. Eligible articles underwent full-text analysis. Each study was systematically evaluated based on predefined parameters such as the demographic groups examined, diagnostic approaches described – including symptomatology and diagnostic criteria – and reported treatment outcomes. To ensure reliability and precision, findings were cross-verified by the authors. The final dataset was carefully organized and synthesized to provide an overview of the current understanding of aHUS, with emphasis on the complement inhibitors eculizumab and ravulizumab. Their mechanisms of action within the pathophysiology of aHUS and comparative therapeutic profiles were also analyzed. Overall, a total of 9 studies from PubMed were selected for inclusion in the systematic review on atypical hemolytic-uremic syndrome.

Results

Etiology and pathomechanism

Atypical hemolytic-uremic syndrome (aHUS) is a rare, life-threatening disease resulting from dysregulation of the complement system [4, 10]. It is also frequently described as a genetic disorder [2, 8]. In approximately 50% of patients with aHUS, a hereditary (mutations in the CFH, CFI, CD46, CFB, and C3 genes) or acquired (autoantibodies against factor H [FHAA]) complement abnormality is identified [2]. Mutations in complement genes or autoantibodies against factor H – which lead to increased complement activation – can be identified in these patients [8]. A comprehensive genomic analysis is critical, as genetic susceptibility significantly contributes to the risk of aHUS; however, disease onset typically requires an additional trigger such as infection, pregnancy, or autoimmune disease. Genetic screening and molecular diagnostics are essential in every patient due to genotype–phenotype correlations that predict disease progression and response to therapy. A French nationwide study involving 214 patients reported that 66.3% had complement-mediated disease (including genetic mutations or anti-CFH antibodies) [13–15]. Overall, 61% of patients had mutations in complement genes [15].

The etiology of aHUS may also involve pharmacological treatments, systemic diseases, pregnancy, malignancies, hematopoietic stem cell and organ transplantation, systemic infections, primary glomerulopathies, and monoclonal gammopathies [3]. Mutations in the EXOSC3 gene may result in aHUS that is refractory to eculizumab treatment [2]. The underlying pathogenic mechanism is uncontrolled activation of the alternative complement pathway [4], resulting in systemic TMA and organ injury [8].

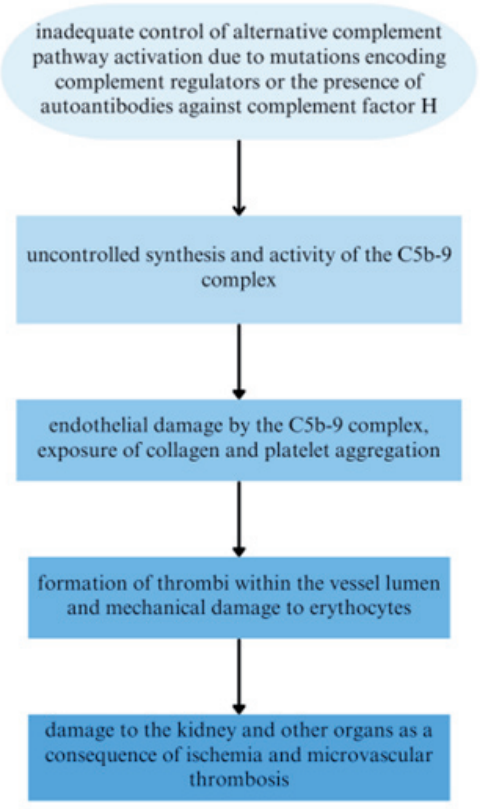

Figure 2. Pathomechanism of atypical hemolytic-uremic syndrome [10]

FExcessive complement activation causes damage and dysfunction of endothelial cells, leading to thrombus formation in the microcirculation [4, 7]. Clinically, this manifests as thrombocytopenia, microangiopathic hemolytic anemia, and acute kidney injury (AKI) [5]. TMA in aHUS may also result in significant morbidity involving other vital organs, including the neurological, cardiovascular, pulmonary, and gastrointestinal systems [6]. TMA describes an etiologically heterogeneous group of diseases resulting from endothelial damage, which leads to sustained thrombotic clot formation in the microcirculation [11–12].

Clinical presentation and diagnostic criteria

Clinically, aHUS manifests as thrombotic microangiopathy (TMA) [1, 5, 6]. Classical features include:

- **thrombocytopenia:** platelet count typically falls below 150×10^9/L [1],
- **microangiopathic hemolytic anemia:** characterized by the destruction of erythrocytes in small vessels, evidenced by elevated lactate dehydrogenase (LDH), the presence of free hemoglobin in serum and urine, and schistocytes on peripheral smear. Erythrocyte damage in partially thrombosed vessels, with schistocyte formation, is mechanical in nature [5, 10],
- **acute kidney injury (AKI):** manifested by increased serum creatinine levels; oliguria or anuria is frequently observed [6, 8]. AKI may be accompanied by proteinuria and hypertension [10].

aHUS may also cause injury to other organs, including [2, 10]:

- central nervous system (altered mental status, seizures),
- cardiovascular system,
- pancreas (pancreatitis),
- liver,
- retina.

The disease often follows a relapsing course, with episodes that may increase in severity and lead to end-stage renal disease (ESRD). Recurrence is common after kidney transplantation [10].

The diagnosis of aHUS is clinical and based on exclusion [2], as no single diagnostic test confirms the disease [1]. Diagnostic criteria include:

- **presence of TMA,** characterized by:

– thrombocytopenia ($<150\times10^9$/L),

– microangiopathic hemolytic anemia (elevated LDH and schistocytes) [6],

- **acute kidney injury,** with elevated serum creatinine.

Differential diagnosis

The differential diagnosis of aHUS primarily involves distinguishing it from other forms of TMA. It is essential to exclude other etiologies of TMA, such as:

- Shiga toxin-producing Escherichia coli HUS (STEC-HUS),

Table 1. TTP versus TMA [11, 13]

Comparison Feature	TTP (Thrombotic Thrombocytopenic Purpura)	aHUS/cmTMA (Complement-Mediated TMA)
Main Pathophysiological Mechanism	Severe deficiency of the ADAMTS13 protease	Dysregulation of the alternative complement pathway
Types	Immune-mediated (iTTP): Antibodies against ADAMTS13. Congenital (cTTP): Hereditary ADAMTS13 deficiency (Upshaw-Schulman syndrome)	Congenital: Mutations in complement regulatory factors (e.g., Factor H, Factor I, MCP/CD46, C3, DGKE, thrombomodulin). Acquired: Antibodies against Factor H (6–10% of cmTMA patients)
Key Diagnostic Test	ADAMTS13 activity below 10 IU/dL. ADAMTS13 testing is the most important specific test to classify TMA	Evidence of complement dysregulation (e.g., sC5b-9, C3, C4, anti-factor H antibody). Diagnosis of cmTMA requires the exclusion of STEC-HUS and TTP
Thrombi (Clot) Composition	Thrombi consist largely of platelets and von Willebrand factor (vWF) and contain little fibrin.	Thrombi are enriched with fibrin and contain less platelets
Dominant Organ Involvement	Thrombi develop mostly in the central nervous system, heart, and kidneys. Severely impaired renal function at diagnosis is not typical for TTP.	Endothelial cell damage mainly affects the capillary region of the kidney. Severely impaired renal function at diagnosis is a characteristic of HUS (including cmTMA).
Prognosis and Course (Untreated)	Untreated lethality is high, at 70–90%. PEX reduced lethality to less than 10%.	Patients present with recurrent episodes of TMA. Permanent renal failure occurs in about 25–30% of cases without specific therapy
Targeted Treatment	TTP: Plasma exchange (PEX) combined with Caplacizumab (anti-vWF antibody). Rituximab for long-term control. cTTP: Plasma therapy or recombinant ADAMTS13 (apadamtase alfa).	C5 complement inhibitors approved for treatment, such as Eculizumab or Ravulizumab. Immunosuppression combined with complement inhibition for anti-factor H antibodies

• thrombotic thrombocytopenic purpura (TTP) – typically by demonstrating severe ADAMTS13 deficiency (<10%),

• pneumococcal HUS (positive Coombs test and/or Streptococcus pneumoniae culture),

• drug-induced TMA,

• TMAs associated with systemic diseases, pregnancy, malignancies, hematopoietic stem cell or organ transplantation, systemic infections, primary glomerulopathies, monoclonal gammopathies,

• disseminated intravascular coagulation (DIC) [1–3].

Additional diagnostic workup includes:

• **genetic testing** to identify complement gene mutations (e.g., CFH, CFI, CD46, CFB, C3, DGKE). Pathogenic mutations are identified in approximately 60–70% of patients [1],

• **serological assays** to detect factor H autoantibodies (FHAA) [2].

Diagnosis is based on clinical TMA and AKI after excluding other causes of TMA. Laboratory evaluation may assist in demonstrating complement dysregulation but is not mandatory for diagnosis. In secondary aHUS, TMA occurs in the context of an underlying condition, and diagnosis requires confirming this association [1, 3].

The classic diagnostic triad defining TMA includes DAT-negative hemolytic anemia with schistocytes, thrombocytopenia, and ischemic end-organ damage. Renal involvement is predominant [11–12].

The principal pathogenic mechanism of aHUS is uncontrolled activation of the alternative complement pathway (AP), leading to continuous cleavage of C5 and sustained complement activation. Dysregulation may result from loss-of-function mutations in regulatory proteins (e.g., CFH, CFI, MCP/CD46, THBD) or gain-of-function mutations in activation factors (e.g., C3, CFB). Prompt and accurate classification of TMA is therefore essential [16–20].

Treatment of atypical hemolytic-uremic syndrome

The treatment of aHUS has evolved with improved understanding of its pathomechanism, which involves uncontrolled activation of the alternative complement pathway [5, 6]. Before the development of terminal complement inhibitors, management primarily relied on plasma exchange (PE) or plasma infusion (PI). However, these approaches often failed to alter the disease course and were associated with significant morbidity and mortality [5]. Historically, 64% of adults with aHUS developed ESRD or died within 3–5 years of disease onset. Despite PE/PI, prognosis remained poor, with 56% requiring renal replacement therapy or dying within one year, and 67% progressing to ESRD or dying within three years [5]. Eculizumab, a C5 inhibitor, was approved for the treatment of aHUS and demonstrated improvements in hematologic and renal parameters in prospective phase 2 studies [6]. It is considered a safe and effective treatment. In the study by Cofiell et al., eculizumab improved multiple dysregulated physiological pathways in aHUS, demonstrating the importance of sustained terminal complement blockade – even when laboratory values improve. In the study by Fakhouri et al., eculizumab led to hematologic normalization and improved renal function. The median time to platelet normalization was 8 days (range 0–84), and to LDH normalization 54 days (range 2–146) [6]. Prompt initiation is correlated with improved renal recovery. Eculizumab is the standard of care for preventing post-transplant recurrence, especially in patients with complement gene mutations. A systematic review and meta-analysis confirmed its efficacy in this population.

Eculizumab treatment resulted in:

• reduced likelihood of aHUS recurrence (OR=0.05),

• significant reduction in need for dialysis (OR=0.13),

• lower serum creatinine (MD=126.931 μmol/L),

• improved estimated GFR (MD=59.571 mL/min),

• reduced likelihood of rejection (OR=0.09),

• improvements in TMA parameters – platelet counts (MD=163.421/mm^3) and LDH (MD=336.608 U/L).

Currently, complement inhibition – primarily with eculizumab – represents the mainstay of aHUS treatment [1, 21–23]. Ravulizumab, a long-acting C5 inhibitor, has also demonstrated safety and efficacy in adults with aHUS naïve to complement inhibitors. In secondary aHUS (a heterogeneous group of TMAs), eculizumab use is considered case-dependent. A study by Cordero et al. found no significant difference in renal response between treated and untreated patients. However, ex vivo studies show C5b-9 deposition in endothelial cells exposed to sera from secondary TMA patients, supporting a role for complement activation. Thus, eculizumab is considered a reasonable therapeutic option. Monitoring may include complement functional assays [1, 3, 8]. Meningococcal disease is a known risk during eculizumab therapy, even in vaccinated patients. Prophylaxis should continue for two weeks after treatment discontinuation [5, 7]. Studies are underway evaluating the feasibility of eculizumab discontinuation in aHUS patients in remission. Relapse criteria include changes in platelet count, LDH, and creatinine [7].

Comparison of eculizumab and ravulizumab

Both eculizumab and ravulizumab are inhibitors of the terminal complement pathway used in the treatment of atypical hemolytic-uremic syndrome (aHUS) [4]. Ravulizumab was engineered from eculizumab to extend its elimination half-life, enabling longer dosing intervals of up to eight weeks instead of every two weeks [1]. The efficacy and safety of eculizumab have been established in previous clinical trials and real-world evidence. Prospective studies in adults demonstrated its effectiveness in treating aHUS, with rapid initiation associated with improved renal recovery.Long-term observational data indicate that patients maintained on eculizumab experience rapid and sustained improvements in eGFR for up to six years [1, 5, 6]. Ravulizumab, evaluated in a prospective phase III study of adult patients with aHUS who were naïve to complement inhibitors, rapidly resolved aHUS-related thrombotic microangiopathy (TMA). The primary endpoint – complete TMA response – was achieved in 53.6% of patients [1]. Improvements in platelet count, LDH normalization, and at least a 25% reduction in serum creatinine were observed in 83.9%, 76.8%, and 58.9% of patients, respectively. An improvement in eGFR by one or more categories by day 183 occurred in 68.1% of patients with available data [1]. As with eculizumab, ravulizumab achieved immediate, complete, and sustained inhibition of C5 in all participants [1]. Ravulizumab has also been shown to be effective and safe in complement inhibitor-naive pediatric patients with aHUS [3]. However, the ravulizumab trial was not directly comparative to eculizumab, making direct comparisons inappropriate [4]. Nevertheless, the results from prior eculizumab studies provide some context [4]. The eculizumab adult study (C10-004) had similar endpoints, evaluating hematological parameters and renal function. However, it is important to note significant differences in study design, such as the permitted use of PE in the initial treatment period in the C10-004 (eculizumab) study, which was not the case in the ravulizumab study. Additionally, the definition of dialysis at baseline was more restrictive in the ravulizumab study, complicating direct outcome comparisons [1]. Both eculizumab and ravulizumab are potent inhibitors of the terminal complement pathway. Indirect comparisons of clinical trial data suggest comparable efficacy between ravulizumab and eculizumab in the treatment of aHUS. Both eculizumab and ravulizumab are potent terminal complement inhibitors targeting C5 [4, 7]. Indirect comparisons of trial data suggest that the two agents have comparable efficacy in the treatment of aHUS. Ravulizumab's extended half-life allows for less frequent administration (every 8 weeks) compared with eculizumab (every 2 weeks) [1]. Both drugs have been shown to improve hematologic parameters and renal function [1, 6]. Direct comparative clinical trials, however, have not yet been performed. The safety profiles of both drugs are similar. Meningococcal infection remains a recognized risk with eculizumab despite prior vaccination, and this risk is presumed to apply to ravulizumab as well due to their shared mechanism of action. The therapeutic landscape for complement-mediated diseases continues to expand, with several novel agents targeting different points of the complement cascade:

- Pegcetacoplan (C3 inhibitor): this drug binds to the C3 component, preventing its cleavage and subsequent activation. While approved for paroxysmal nocturnal hemoglobinuria (PNH), it is being studied for other complement-mediated glomerulopathies, including C3 Glomerulopathy (C3G). In a Phase 2 study of C3G, pegcetacoplan met the primary endpoint of proteinuria reduction, achieving a mean individual reduction of 50.9% in the ITT population at Week 48. Although currently there are no published studies for aHUS, its proximal blocking mechanism suggests potential benefit.
- Iptacopan (CFB inhibitor): iptacopan is an oral Factor B (CFB) inhibitor, targeting the AP. It is currently being studied in C3G and a Phase II clinical trial is underway to evaluate its efficacy in patients with aHUS.
- Crovalimab (Anti-C5): a novel anti-C5 monoclonal antibody utilizing Sequential Monoclonal Antibody Recycling Technology (SMART). This technology results in efficient C5 binding and recycling. Clinical trials are ongoing for pediatric, adolescent, and adult aHUS patients.
- Narsoplimab (Anti-MASP2): a humanized anti-MASP2 monoclonal antibody targeting the lectin pathway, primarily indicated for TMA associated with bone marrow transplantation (BMT), with no relevant evidence yet for use in aHUS. [1,5,6, 24-30].

Limitations

This review has several limitations that should be considered when interpreting its findings. First, the heterogeneity of the included study populations, particularly the wide age range, may have introduced variability in outcomes and treatment responses. Second, diagnostic criteria should consider differential diagnoses and account for the potential presence of secondary atypical hemolytic-uremic syndrome (aHUS) as a manifestation of an underlying primary disease. Finally, variability in treatment responses to eculizumab and ravulizumab, combined with the absence of direct head-to-head trials between these two

terminal complement inhibitors, highlights an important area for future research aimed at optimizing aHUS management in specific patient subgroups.

Conclusions

Atypical hemolytic-uremic syndrome (aHUS) is a rare, life-threatening disease caused by uncontrolled activation of the complement system, leading to systemic thrombotic microangiopathy (TMA) and multi-organ damage. This review provides a comprehensive overview of the current understanding of aHUS, emphasizing its etiology, which is linked to dysregulation of the alternative complement pathway and frequently associated with genetic mutations or acquired autoantibodies. Clinically, aHUS presents with the triad of thrombocytopenia, microangiopathic hemolytic anemia, and acute kidney injury, and diagnosis relies on excluding other causes of TMA. Differential diagnosis is essential and includes ruling out STEC-HUS, TTP, and secondary forms of TMA. The treatment landscape of aHUS has been transformed with the introduction of terminal complement inhibitors, such as eculizumab and ravulizumab. Both drugs have demonstrated efficacy in improving hematological and renal parameters. Ravulizumab, with its longer half-life, allows for less frequent dosing compared with eculizumab. Although direct comparative studies are lacking, available evidence suggests comparable efficacy between the two agents in the treatment of aHUS. Ongoing research is exploring the feasibility of discontinuing eculizumab in patients in remission, with monitoring criteria for potential relapse. This review underscores the importance of early diagnosis and timely initiation of complement inhibitor therapy. Future studies should focus on optimizing treatment regimens, identifying predictive factors for therapeutic response, and improving understanding of secondary aHUS and its responsiveness to complement-targeted therapy. Direct head-to-head trials comparing eculizumab and ravulizumab would provide valuable insights for refining treatment strategies in aHUS.

References

1. **Rondeau** E, Scully M, Ariceta G, Barbour T, Cataland S, Heyne N, et al. The long-acting C5 inhibitor, Ravulizumab, is effective and safe in adult patients with atypical hemolytic uremic syndrome naïve to complement inhibitor treatment. Kidney International 2020; 97(6): 1287–96.
2. **Brocklebank** V, Walsh PR, Smith-Jackson K, Hallam TM, Marchbank KJ, Wilson V, et al. Atypical hemolytic uremic syndrome in the era of terminal complement inhibition: an observational cohort study. Blood 2023; 142(16): 1371–86.
3. **Cordero** L, Cavero T, Gutiérrez E, Trujillo H, Sandino J, Auñón P, et al. Rational use of eculizumab in secondary atypical hemolytic uremic syndrome. Frontiers in Immunology 2024; 14: 1310469.
4. **Cammett** TJ, Garlo K, Millman EE, Rice K, Toste CM, Faas SJ. Exploratory prognostic biomarkers of complement-mediated thrombotic microangiopathy (CM-TMA) in adults with atypical hemolytic uremic syndrome (aHUS): analysis of a phase III study of Ravulizumab. Molecular Diagnosis & Therapy 2023; 27(1): 61–74.
5. **Menne** J, Delmas Y, Fakhouri F, Licht C, Lommelé Å, Minetti EE, et al. Outcomes in patients with atypical hemolytic uremic syndrome treated with eculizumab in a long-term observational study. BMC Nephrology 2019; 20(1): 125.
6. **Fakhouri** F, Hourmant M, Campistol JM, Cataland SR, Espinosa M, Gaber AO, et al. Terminal complement inhibitor eculizumab in adult patients with atypical hemolytic uremic syndrome: a single-arm, open-label trial. Am J Kidney Dis 2016; 68(1): 84–93.
7. **Dunn** S, Brocklebank V, Bryant A, Carnell S, Chadwick TJ, Johnson S, et al. Safety and impact of eculizumab withdrawal in patients with atypical haemolytic uraemic syndrome: protocol for a multicentre, open-label, prospective, single-arm study. BMJ Open 2022; 12(9): e054536.
8. **Cofiell** R, Kukreja A, Bedard K, Yan Y, Mickle AP, Ogawa M, et al. Eculizumab reduces complement activation, inflammation, endothelial damage, thrombosis, and renal injury markers in aHUS. Blood 2015; 125(21): 3253–62.
9. **Page** MJ, McKenzie JE, Bossuyt PM, Boutron I, Hoffmann TC, Mulrow CD, et al. The PRISMA 2020 statement: an updated guideline for reporting systematic reviews. BMJ 2021; 372: n71.
10. **Litwin** M, Grenda R. Atypical hemolytic uremic syndrome. In: Nefrologia dziecięca w praktyce (od A do Z). 1st ed. Kraków: Medycyna Praktyczna, 2021: 255-257. (In Polish).
11. **Bommer** M, Bloehdorn J. Microangiopathic anemia. Transfus Med Hemother 2025; 52(4): 259-270.
12. **Shahid** K, Qayyum S. Eculizumab versus Ravulizumab for the treatment of atypical hemolytic uremic syndrome: a systematic review. Cureus 2023; 15(9): e46185.
13. **Loirat** C, Fakhouri F, Ariceta G, Besbas N, Bitzan M, Bjerre A, et al. An international consensus approach to the management of atypical hemolytic uremic syndrome in children. Pediatr Nephrol 2016; 31(1): 15-39.
14. **Vonbrunn** E, Büttner-Herold M, Amann K, Daniel C. Complement inhibition in kidney transplantation: where are we now? BioDrugs 2023; 37(1): 5-19.
15. **Fremeaux-Bacchi** V, Fakhouri F, Garnier A, Bienaimé F, Dragon-Durey MA, Ngo S, et al. Genetics and outcome of atypical hemolytic uremic syndrome: a nationwide French series comparing children and adults. Clin J Am Soc Nephrol 2013; 8(4): 554-62.
16. **Goodship** TH, Cook HT, Fakhouri F, Fervenza FC, Frémeaux-Bacchi V, Kavanagh D, et al. Atypical hemolytic uremic syn-

drome and C3 glomerulopathy: conclusions from a "Kidney disease: improving global outcomes" (KDIGO) controversies conference. Kidney Int 2017; 91(3): 539-551.
17. **Kelen** K, Horváth O, Kis É, Mikes B, Sallay P, et al. Immunosuppressive therapy of antibody-mediated aHUS and TTP. Int J Mol Sci 2023; 24(18): 14389.
18. **Bogdan** RG, Anderco P, Ichim C, Cimpean AM, Todor SB, et al. Atypical hemolytic uremic syndrome: a review of complement dysregulation, genetic susceptibility and multiorgan involvement. J Clin Med 2025; 14(7): 2527.
19. **Legendre** CM, Licht C, Muus P, Greenbaum LA, Babu S, Bedrosian C, Bingham C, et al. Terminal complement inhibitor eculizumab in atypical hemolytic-uremic syndrome. N Engl J Med 2013; 368(23): 2169-81.
20. **Gülhan** B, Özaltın F, Fidan K, Özçakar ZB, Söylemezoğlu O. Management of pediatric hemolytic uremic syndrome. Turk J Pediatr 2024; 66(1): 1-16.
21. **Nester** CM, Barbour T, de Cordoba SR, Dragon-Durey MA, Fremeaux-Bacchi V, Goodship TH, et al. Atypical aHUS: state of the art. Mol Immunol 2015; 67(1): 31-42.
22. **Tang** ZC, Hui H, Shi C, Chen X. New findings in preventing recurrence and improving renal function in AHUS patients after renal transplantation treated with eculizumab: a systemic review and meta-analyses. Ren Fail 2023; 45(1): 2231264.
23. **Noris** M, Remuzzi G. Atypical hemolytic-uremic syndrome. N Engl J Med 2009; 361(17): 1676-87.
24. **Dixon** BP, Greenbaum LA, Huang L, Rajan S, Ke C, Zhang Y, Li L. Clinical safety and efficacy of pegcetacoplan in a phase 2 study of patients with C3 glomerulopathy and other complement-mediated glomerular diseases. Kidney Int Rep 2023; 8(11): 2284-2293.
25. **Vaisbich** MH, Andrade LGM, Barbosa MINH, Castro MCR, Miranda SMC, Poli-de-Figueiredo CE, et al. Recommendations for diagnosis and treatment of atypical hemolytic uremic syndrome (aHUS): an expert consensus statement from the rare diseases committee of the Brazilian society of nephrology (COMDORA-SBN). J Bras Nefrol 2025; 47(2): e20240087.
26. **Schönfelder** K, Kühne L, Schulte-Kemna L, et al. Clinical efficacy and safety of switching from eculizumab to ravulizumab in adult patients with aHUS- real-world data. BMC Nephrol 2024; 25(1): 202.
27. **Scully** M, Cataland S, Coppo P, et al. International working group for thrombotic thrombocytopenic purpura. Consensus on the standardization of terminology in thrombotic thrombocytopenic purpura and related thrombotic microangiopathies. J Thromb Haemost 2017;15(2): 312-322.
28. **Ariceta** G, Fakhouri F, Sartz L, Miller B, et al. Eculizumab discontinuation in atypical haemolytic uraemic syndrome: TMA recurrence risk and renal outcomes. Clin Kidney J 2021; 14(9): 2075-2084.
29. **Thomas** K, Ananthula A, Lopez-Flores R, Toro AD, Chapple AG, Loch M. The use of eculizumab for the treatment of atypical hemolytic uremic syndrome in an academic hematology center. Perm J 2023; 27(2): 23-30.
30. **Wong** EKS, Kavanagh D. Diseases of complement dysregulation-an overview. Semin Immunopathol 2018; 40(1): 49-64.

Word count: 3088 • Tables: 1 • Figures: 2 • References: 30

Sources of funding:
The research was funded by the authors.

Conflicts of interests:
The authors report that there were no conflicts of interest.

Cite this article as:
Turek M, Szlążek J, Zagalska M, Kerknawi K, Ząbek AJ, Grzebinoga A, Kuźniar JP, Chrzanowska EG, Roguska B, Tamborski T.
Atypical hemolytic-uremic syndrome (aHUS) – a rare disease, new hopes in treatment: a systematic review.
Med Sci Pulse 2025;19(4):51–59. DOI: 10.5604/01.3001.0055.4601.

Corresponding author:
Marta Turek
Email: martaturek74@gmail.com
Independent Public Clinical Hospital
named Andrzej Mielęcki
of the Silesian Medical University in Katowice
Francuska 20-24 Street
40-027 Katowice, Poland

Other authors/contact:
Julia Szlążek
Email: juliaszlazek@gmail.com

Michalina Zagalska
Email: michalina.zagalska24@gmail.com

Kamil Kerknawi
Email: Kerknaw@gmail.com

Adam Jan Ząbek
Email: adamzabek@vp.pl

Adam Grzebinoga
Email: adam.grzebinoga99@wp.pl

Jakub Paweł Kuźniar
Email: kuba.kuzniar@gmail.com

Emilia Gabriela Chrzanowska
Email: chrzanowska.e@gmail.com

Barbara Roguska
Email: b.m.c.roguska@gmail.com

Tomasz Tamborski
Email: tomasztam97@gmail.com

Sent to editorial office: 24 April 2025
Accepted after review: 14 November 2025
Published: 19 December 2025